



PATIENT

Nova Bazinet

SPECIES

Canine

BREED

American Bulldog

SEX

Female

AGE

2 years

WEIGHT

45.9kgs

INTERPRETED BY

Maggie Machen Lamy,
DVM, DACVIM
(Cardiology)

IMAGING PERFORMED BY

Nigel Gumley, DVM

HOSPITAL NAME

Cedarview Animal
Hospital

REFERRING VET

Dr. Gumley

INVOICE

22345

DATE

12/8/21

PRESENTING CLINICAL SIGNS

History: Grade 2/6 L apical heart murmur heard but intermittently during exam. No clinical signs of heart disease. Is a breeding female. Butorphanol given for exam but persistently elevated BP measurements in clinic likely due to stress.

-Abnormal PE/Chem/CBC/UA Results: MM pink, Lung sounds normal, normal CRT. Femoral pulses normal, bright and alert.

ECHOCARDIOGRAM FINDINGS

2D, m-mode, color flow and doppler imaging is available. Minimal diffuse thickening of mitral valve leaflets with no obvious prolapse into the left atrial lumen. No mitral regurgitation is identified. Normal left atrial dimension. Normal LV diameter with adequate myocardial function. The tricuspid valve appears subjectively normal, with no tricuspid regurgitation. The right heart is normal (subjective). No overt evidence of pulmonary arterial hypertension. The pulmonic and aortic valves are normal in morphology and mobility. No aortic abnormalities identified, however the LVOT velocity is mildly elevated. Normal pulmonic outflow velocities. No aortic or pulmonic insufficiency. No pericardial or pleural effusion noted. No cardiac tumors observed.

CARDIAC CHART

CANINE CARDIAC PARAMETERS	MR VMAX (m/s)	TR VMAX (m/s)	LA/AO (Boon method)	LA/AO (Heart Base; Swe)	FS (%)	EF (%)	EPSS (cm)
NORMAL PARAMETER	4.5-5.5	<2.7	1.3	<1.6	28-40	40-100	<0.6
PATIENT	NA	NA	1.1	1.4	53	82	0.3
CANINE CARDIAC PARAMETERS	HR (BPM)	AV VMAX (m/s)	PV MAX (m/s)	BODY WEIGHT (kg)	LA 2D short axis Base view (cm)	LVIDd Avg; 2D and m-mode short axis (cm)	LVIDs Avg; 2D and m-mode short axis (cm)
NORMAL PARAMETER	50-100	0.7-1.7	0.7-1.6	BELOW	BELOW	BELOW	BELOW
PATIENT	183	2.2	1.5	45.9	1.9	4.6	2.1
*Normal chamber parameters expressed as a mean value (SD)				3	1.27 (5.3)	2.46 (2.46)	1.36 (5.5)
BODY WEIGHT DEPENDENT PARAMETERS				5	1.40 (4.5)	2.74 (5.2)	1.60 (4.7)
<i>*Note: All measurements based upon multi-modal images and methods. An average value is reported.</i>				10	1.50 (3.8)	3.27 (3.5)	2.06 (3.1)
				15	1.83 (2.0)	3.71 (2.4)	2.43 (2.1)
				20	2.02 (1.9)	4.14 (2.2)	2.80 (2.0)
				25	2.18 (2.4)	4.48 (2.9)	3.10 (2.5)
				30	2.33 (3.3)	4.83 (3.9)	3.39 (3.4)
				35	2.48 (4.3)	5.17 (5.0)	3.69 (4.5)
				40	2.62 (5.2)	5.48 (6.1)	3.96 (5.4)
				50	2.88 (7.1)	6.07 (8.3)	4.46 (7.4)

INTERPRETATION OF THE FINDINGS & FURTHER RECOMMENDATIONS

The only cause of a murmur identified is increased flow velocity through the LVOT/aortic root. No obvious subaortic ridge or valvular abnormalities are visualized, and in the absence of structural abnormalities this is considered a benign flow murmur. If this is a new murmur, it is reasonable to monitor periodically via recheck echocardiography in the future. Additionally, screening for fluid status abnormalities (dehydration, anemia, etc.) is recommended through routine lab work as these



PATIENT

Nova Bazinet

abnormalities would make this finding more prevalent. No significant valvular insufficiencies were noted, and no structural issues identified.

SPECIES

Canine

No cardiac medications are indicated. No cardiac contraindication for general anesthesia.

BREED

American Bulldog

No obvious contraindication for breeding this animal. That being said, **an official OFA examination by an Attending Cardiologist is considered the gold standard prior to breeding and should be considered.** The cut-off for aortic outflow anomalies is 2.2m/s, making this patient extremely borderline.

SEX

Female

Monitor for any development of cough, labored breathing or exercise intolerance.

AGE

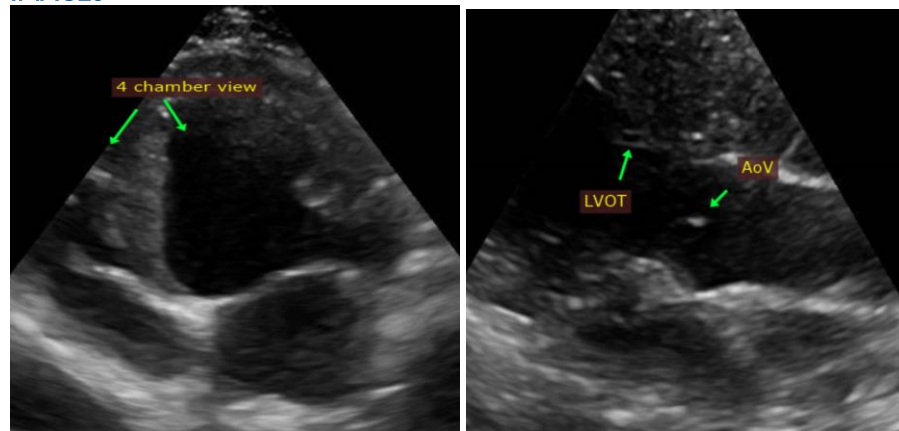
2 years

Recommend recheck echocardiogram annually to screen for development of disease.

WEIGHT

45.9kgs

IMAGES



INTERPRETED BY

Maggie Machen Lamy,
DVM, DACVIM
(Cardiology)

The information and recommendations provided are based on the images presented by the referring veterinarian. No evaluation can be communicated regarding pathology that was not visible in the image/video clips provided.

IMAGING PERFORMED BY

Nigel Gumley, DVM

Thank you for this referral. This report was generated using transcription software, and minor dictation errors may be present. If the clinical or image interpretation does not parallel your findings or if I can be of any further assistance, please contact me.

HOSPITAL NAME

Cedarview Animal
Hospital

Maggie Machen Lamy, DVM
Diplomate of the American College of Veterinary Internal Medicine (Cardiology)
info@sonopath.com

REFERRING VET

Dr. Gumley

INVOICE

22345

DATE

12/8/21